

Early Neonatal SARS-CoV-2 Infection Manifesting With Hypoxemia Requiring Respiratory Support

MT Sinelli, MD, G Paterlini, MD, M Citterio, MD, A Di Marco, MD, T Fedeli, MD, ML Ventura, MD

DOI: 10.1542/peds.2020-1121

Journal: *Pediatrics*

Article Type: Case Report

Citation: Sinelli MT, Paterlini G, Citterio M, et al. Early neonatal SARS-CoV-2 infection manifesting with hypoxemia requiring respiratory support. *Pediatrics*. 2020; doi: 10.1542/peds.2020-1121

This is a pre-publication version of an article that has undergone peer review and been accepted for publication but is not the final version of record. This paper may be cited using the DOI and date of access. This paper may contain information that has errors in facts, figures, and statements, and will be corrected in the final published version. The journal is providing an early version of this article to expedite access to this information. The American Academy of Pediatrics, the editors, and authors are not responsible for inaccurate information and data described in this version.

Early Neonatal SARS-CoV-2 Infection Manifesting With Hypoxemia Requiring Respiratory Support

MT Sinelli, MD¹, G Paterlini, MD¹, M Citterio, MD¹, A Di Marco, MD¹, T Fedeli, MD¹, ML Ventura,
MD¹

Affiliations: 1 Neonatal Intensive Care Unit, Fondazione MBBM-ASST-Monza, Monza, Italy

Address correspondence to: Mariateresa Sinelli MD, Neonatal Intensive Care Unit, Fondazione MBBM-ASST-Monza, via Pergolesi 33, 20900, Monza, Italy (mtsinelli@gmail.com)

Financial Disclosure: Authors have no financial relationships relevant to this article to disclose.

Funding: none.

Conflict of Interest: The other authors have no conflicts of interest to disclose.

Abbreviations: none

Short title: Sars-Cov-2 infection in a newborn: a case report

Contributors' Statement:

Dr Sinelli conceptualized and designed the study, drafted the initial manuscript, reviewed and revised the manuscript.

Dr Paterlini, Citterio, Di Marco and Fedeli collected data, carried out the analysis, reviewed and revised the manuscript.

Dr Ventura designed the data collection instruments, coordinated and supervised data collection, and critically reviewed the manuscript.

All authors approved the final manuscript as submitted and agree to be accountable for all aspects of the work.

Abstract

We describe a case of neonatal SARS-CoV-2 infection, diagnosed 3 days after birth, and manifesting with silent hypoxemia, requiring respiratory support.

Background

In December 2019, an emergent new coronavirus was detected in Wuhan, China as the cause of severe pneumonia¹. The virus, named SARS-CoV-2, causes a disease named COVID-19 and has become pandemic². At the end of February, a cluster of cases was identified in Northern Italy. Since then, SARS-CoV-2 has been responsible for more than 80,000 infections among Italian adults, with about 10 neonatal cases detected. The disease seems to be mild in children and, to date, there are few reports in neonatal population. It is still not clear if there is vertical transmission of virus from mother to newborn and there is not a consensus on the appropriate infection control precautions to be used in the care of the newborn. We report a case of COVID-19 infection in a term newborn who required respiratory support after a vaginal delivery.

Case report

The baby was born at term after an uneventful pregnancy. On admission, mother was asymptomatic and afebrile. An uncomplicated vaginal delivery ensued resulting in an appropriate for gestational age male infant. Delayed cord clamping and skin-to-skin contact were performed, as part of the routine care. Apgar scores were assigned as 9 and 10 at 1 and 5 minutes, respectively. On the second day after delivery, the mother became febrile with no respiratory symptoms. Her nasopharyngeal swab was positive for SARS-CoV-2 (qualitative PCR), while other causes of fever were ruled out. A nasopharyngeal swab obtained that same day on the infant was also positive for SARS-CoV-2. On examination, the infant's clinical condition was good and he demonstrated no signs of lung or organ system disease. The infant and the mother were not separated and they were both transferred to an airborne-isolation zone to continue the follow-up. However, 48 hours after isolation, the newborn developed perioral cyanosis and poor sucking without signs of respiratory distress. Oxygen saturation on room air was 88%, respiratory rate was 15-20

per minute, heart rate was 120 bpm, and blood pressure was normal range. Arterial blood gas analysis demonstrated moderate hypoxia (Table 1). A complete blood count and differential and C-reactive protein were normal. An echocardiogram excluded any cardiac abnormalities. Empiric treatment with ampicillin and gentamicin was initiated but discontinued when blood and urine culture were sterile. Qualitative PCR on the nasopharyngeal swab specimen was negative for other respiratory virus (influenza A and B, parainfluenza, respiratory syncytial virus, adenovirus, metapneumovirus, rhinovirus, enterovirus, bocavirus and minor type of Coronavirus). The baby was admitted to the neonatal intensive care unit and placed on 30% inspired oxygen via high-flow nasal cannula. Chest radiograph showed mild bilateral ground-glass opacities and lung ultrasound did not reveal consistent abnormalities (Figure 1). After 36 hours, a chest CT-scan did not show major abnormalities. The infant's condition improved, respiratory support was discontinued 50 hours after admission to the neonatal intensive care unit. The infant was fed maternal expressed milk by nasogastric tube for 48 hours, after which he was able to be fully bottle fed. The infant was discharged in good condition on day 18 of life. On days 15 and 21 of life, his qualitative PCR for COVID-19 remained positive.

Discussion

This report details a case of neonatal Sars-CoV-2 infection that presented on day of life 5 with clinically significant hypoxemia without overt signs of respiratory distress that required oxygen therapy (Figure 2). Although clinical manifestations of COVID-19 among pediatric patients are generally less severe than those of adults,³ the proportion of severe and critical cases reported in children is inversely correlated with their age, with more severe cases in infants less than 1 year old.⁴ Nonetheless, early Chinese case series of newborns were reassuring, reporting either asymptomatic courses with only radiologic finding of disease⁵ or very rarely symptomatic and uncomplicated diseases.⁶

Our case demonstrates, however, that significant hypoxemia can occur in newborns with early SARS-CoV-2 infection. In these cases, diagnosis can be challenging because clinical manifestation of respiratory failure, such as polypnea or respiratory distress, may be absent.

Despite the large number of people with confirmed COVID-19 infection, very few cases have occurred in newborn infants. Data are not sufficient at this time to allow a clear evidence-based recommendation for optimal infection control measures in newborns of mothers with COVID-19 infection. Our case report suggests that a newborn infected with SARS-CoV-2 may not demonstrate signs of respiratory distress but may have significant hypoxia that requires treatment. Pulse oximetry monitoring may be advisable prior to the discharge of healthy appearing infants with positive testing for SARS-CoV-2. In addition, parents should be trained to recognize signs of possible hypoxemia, such as poor sucking or changes in baby's skin color.

In our patient, nasopharyngeal swab remained positive for more than two weeks, unlike previous reports showing rapid virologic clearance.⁶ Together with previous reports of frequent asymptomatic infections, our finding suggests that newborns could be a source of horizontal transmission of the infection and should be managed accordingly.

In conclusion, it is important to remind that in the case of neonatal Sars-Cov-2 infection, especially if it occurs in an early period of life, the disease might have insidious onset. Based on our report, we suggest to strictly monitor infants born from infected mothers in the first week of life.

Acknowledgments

Thank you to Dr. Giuseppe Lapadula for his review of the manuscript.

References

1. The Novel Coronavirus Pneumonia Emergency Response Epidemiology Team. The Epidemiological Characteristics of an Outbreak of 2019 Novel Coronavirus Diseases (COVID-19) -China, 2020. *China CDC Weekly* 2020; 2(8): 113-22. doi: 10.3760/cma.j.issn.0254-6450.2020.02.003
2. [https://www.who.int/dg/speeches/detail/who-director-general-s-statement-on-ihf-emergency-committee-on-novel-coronavirus-\(2019-ncov\)](https://www.who.int/dg/speeches/detail/who-director-general-s-statement-on-ihf-emergency-committee-on-novel-coronavirus-(2019-ncov)). Accessed 3/3/2020.
3. Systematic review of COVID-19 in children shows milder cases and a better prognosis than adults. JF Ludvigsson. *Acta Paediatr* 2020 Mar 23. doi: 10.1111/apa.15270

4. Epidemiological Characteristics of 2143 Pediatric Patients With 2019 Coronavirus Disease in China. Yuanyuan Dong, Xi Mo, Yabin Hu, Xin Qi, Fang Jiang, Zhongyi Jiang, Shilu Tong. *Pediatrics*. 2020. doi: 10.1542/peds.2020-0702
5. A Case Report of Neonatal 2019 Coronavirus Disease in China. Shaoshuai Wang, Lili Guo, Ling Chen, Weiyong Liu, Yong Cao, Jingyi Zhang, Ling Feng. *Cl Infect Dis* 2020; doi.org/10.1093/cid/ciaa225 Epub 2020 Mar 12. doi: 10.1016/S0140-6736(20)30360-3
6. Neonatal Early-Onset Infection With SARS-CoV-2 in 33 Neonates Born to Mothers With COVID-19 in Wuhan, China. Zeng L, Xia S, Yuan W, Yan K, Xiao F, Shao J, Zhou W. *JAMA Pediatr*. 2020 Mar 26. doi: 10.1001/jamapediatrics.2020.0878

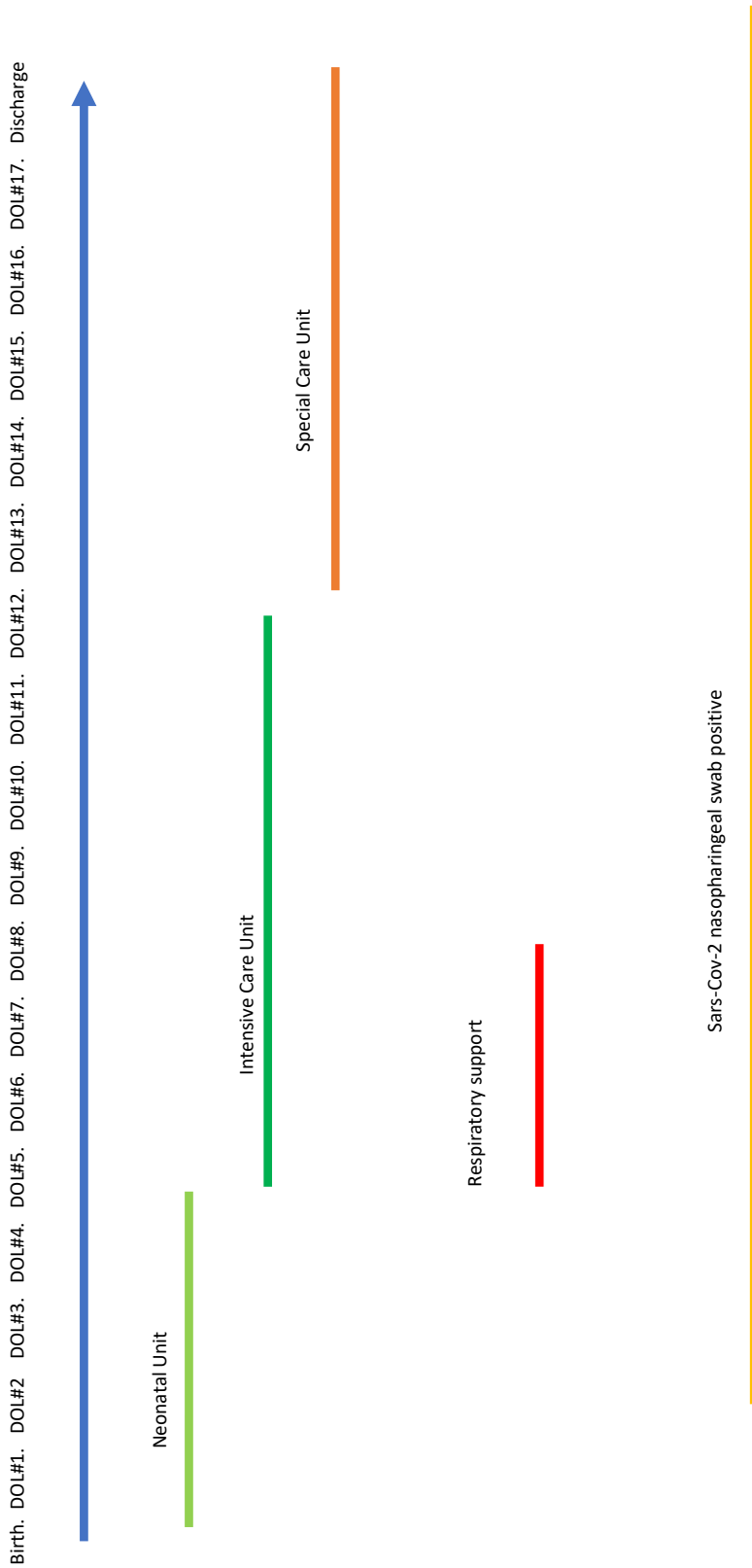
Table 1. Baby's blood test (DOL, days of life)

Time	DOL #5 h12	DOL#5 h 18	DOL#6 h 2
ph	7.49	7.40	7.45
paCO2 mmHg	31	39.5	29.1
paO2 mmHg	48	48.2	93.9
HCO3- mmol/L	23	24	19.6
BE	1.1	-0.5	-2.6
CRP mg/dl	0.1		0.06
WBC /mm3	6.800		
Hemoglobin g/L	17.2		
Platelets /mm3	456.000		
Neutrophil count %	28%		
Lymphocyte count %	56%		

Figure 1. Chest x-ray of the newborn obtained on DOL#3 showing mild bilateral ground-glass opacities

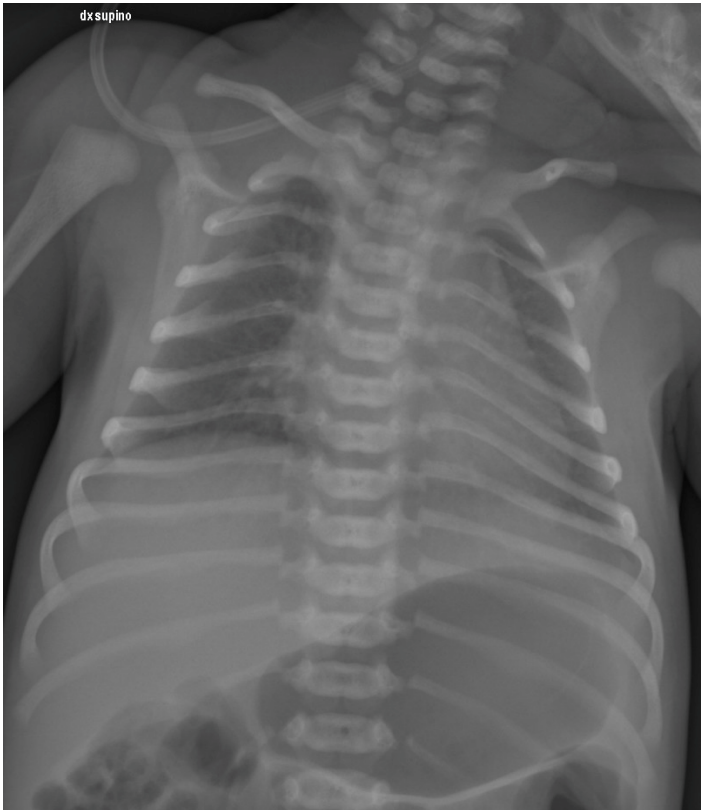

Figure 2. Timeline of our case report from birth to discharge



**Early Neonatal SARS-CoV-2 Infection Manifesting With Hypoxemia Requiring
Respiratory Support**

MT Sinelli, G Paterlini, M Citterio, A Di Marco, T Fedeli and ML Ventura

Pediatrics originally published online May 4, 2020;

**Updated Information &
Services**

including high resolution figures, can be found at:
<http://pediatrics.aappublications.org/content/early/2020/04/30/peds.2020-1121.citation>

Permissions & Licensing

Information about reproducing this article in parts (figures, tables) or in its entirety can be found online at:
<http://www.aappublications.org/site/misc/Permissions.xhtml>

Reprints

Information about ordering reprints can be found online:
<http://www.aappublications.org/site/misc/reprints.xhtml>

American Academy of Pediatrics

DEDICATED TO THE HEALTH OF ALL CHILDREN™



PEDIATRICS®

OFFICIAL JOURNAL OF THE AMERICAN ACADEMY OF PEDIATRICS

Early Neonatal SARS-CoV-2 Infection Manifesting With Hypoxemia Requiring Respiratory Support

MT Sinelli, G Paterlini, M Citterio, A Di Marco, T Fedeli and ML Ventura
Pediatrics originally published online May 4, 2020;

The online version of this article, along with updated information and services, is located on the World Wide Web at:

<http://pediatrics.aappublications.org/content/early/2020/04/30/peds.2020-1121.citation>

Pediatrics is the official journal of the American Academy of Pediatrics. A monthly publication, it has been published continuously since 1948. Pediatrics is owned, published, and trademarked by the American Academy of Pediatrics, 141 Northwest Point Boulevard, Elk Grove Village, Illinois, 60007. Copyright © 2020 by the American Academy of Pediatrics. All rights reserved. Print ISSN: 1073-0397.

American Academy of Pediatrics

DEDICATED TO THE HEALTH OF ALL CHILDREN™

